

# MORPHOLOGIC TRANSITIONS BETWEEN PROLIFERATIVE INFLAMMATORY ATROPHY AND HIGH-GRADE PROSTATIC INTRAEPITHELIAL NEOPLASIA

MATHEW J. PUTZI AND ANGELO M. DE MARZO

## ABSTRACT

**Objectives.** To validate with an independent study that simple atrophy/postatrophic hyperplastic lesions (proliferative inflammatory atrophy [PIA]) often merge directly with high-grade prostatic intraepithelial neoplasia (PIN).

**Methods.** Using radical prostatectomies (n = 14), all high-grade PIN and adenocarcinoma lesions were identified. We examined the two-dimensional topographic relationship between individual high-grade PIN lesions and PIA, between carcinoma lesions and PIA, and between carcinoma lesions and high-grade PIN. To reduce the possibility that high-grade PIN lesions represented intraprostatic dissemination of carcinoma, all specimens contained total carcinoma volumes of less than 0.5 cc.

**Results.** High-grade PIN merged with PIA in 267 (42.5% of high-grade PIN lesions) of 629 lesions, was adjacent in 57 lesions (9%), was near in 233 lesions (37%), and was distant from PIA in 72 lesions (11.5%). Carcinoma did not merge with PIA; it was adjacent in 24 (30.4%) of 79 lesions, was near in 46 lesions (58.2%), and was distant from PIA in 9 lesions (11.4%). Of 79 carcinoma lesions, 18 (23%) merged with high-grade PIN, 11 (14%) were adjacent, 26 (33%) were near, and 24 (30%) were distant from high-grade PIN. Areas of presumed low-grade PIN were often found in association with high-grade PIN and PIA.

**Conclusions.** Morphologic transitions between high-grade PIN and PIA occur frequently. Although the mere topographic relation of the lesions is not definitive proof of a continuum, these results are consistent with a model in which the proliferative epithelium in PIA may progress to PIN and/or adenocarcinoma. UROLOGY 56: 828–832, 2000. © 2000, Elsevier Science Inc.

The high-grade form of prostatic intraepithelial neoplasia (PIN) has been postulated to be the precursor to peripheral zone carcinoma of the prostate.<sup>1</sup> This is based on zonal co-localization,<sup>1,2</sup> morphologic transitions,<sup>3</sup> and phenotypic<sup>4</sup> and molecular genetic<sup>4</sup> similarities between high-grade PIN and carcinoma. Although high-grade PIN is thought to arise from low-grade PIN, which in turn is thought to arise in normal or “active” epithelium,<sup>1,5,6</sup> little is known whether truly normal epi-

thelium gives rise to PIN or whether some other lesion may be involved.

Focal atrophy of the prostate, which includes both simple atrophy<sup>7</sup> and postatrophic hyperplasia,<sup>7–9</sup> is often associated with chronic, and less frequently, acute inflammation. Unlike the type of prostatic atrophy associated with androgen withdrawal/blockade (hormonal atrophy), epithelial cells in simple atrophy/postatrophic hyperplasia have a low frequency of apoptosis<sup>7,10</sup> and are highly proliferative.<sup>7,10–12</sup> In addition, hormonal atrophy occurs diffusely throughout the gland and is not usually associated with inflammation. To simplify terminology and to account for the frequent association with inflammation and a high proliferative index in focal atrophy of the prostate, we introduced the term “proliferative inflammatory atrophy” (PIA).<sup>10</sup>

Repeated bouts of cell injury and regeneration occurring in the setting of immune-mediated oxidant stress predisposes to carcinoma in several or-

*This study was funded in part by Public Health Services grant K08 CA78588-01, NIDDK T32DK07522, and Specialized Program in Research Excellence (SPORE) in Prostate Cancer grant P50CA58236.*

*From the Departments of Pathology and Urology, Johns Hopkins University Medical Institutions, Baltimore, Maryland*

*Reprint requests: Angelo M. De Marzo, M.D., Ph.D., Department of Pathology, Cancer Research Building, Room 153, 1650 Orleans Street, Baltimore, MD 21231*

*Submitted: April 18, 2000, accepted (with revisions): June 30, 2000*

gans.<sup>13</sup> Focal atrophy of the prostate frequently occurs in the peripheral zone and rarely in the central zone.<sup>8,14</sup> Also, many of the proliferating cells in PIA occur in the luminal compartment, which is distinct from normal epithelium, in which most proliferation occurs in the basal compartment. This shift occurs in most carcinoma precursor lesions,<sup>15</sup> including high-grade PIN.<sup>16–19</sup> In terms of biomarker expression, PIA has decreased p27<sup>Kip1</sup>,<sup>10</sup> which may relate to the increased proliferation. Elevated levels of Bcl-2<sup>10</sup> may be responsible for the low levels of cell death in PIA. Finally, many cells in PIA show elevated levels of the carcinogen detoxification enzyme, GSTP1,<sup>10</sup> consistent with a response to oxidant stress.

On the basis of the above data, we recently hypothesized that focal atrophy of the prostate, previously proposed as a carcinoma precursor,<sup>8,20</sup> may be a precursor, but that it may at times progress to carcinoma by way of an intermediate transition to high-grade PIN.<sup>10</sup> If true, focal atrophy and high-grade PIN should occur in spatial proximity. In our recent study to characterize the morphology and immunophenotype of PIA, we noted that 34% of focal atrophy lesions contained areas with atrophic epithelium merging directly within the same acinus/duct with high-grade PIN.<sup>10</sup> This preliminary finding prompted the current study to evaluate the hypothesis that high-grade PIN lesions and/or small carcinomas develop in the setting of PIA.

## MATERIAL AND METHODS

### SPECIMENS AND SPECIMEN PROCESSING

Fourteen fully embedded radical prostatectomy specimens from the Johns Hopkins Hospital were used. The preoperative stage was T1c in all cases. None of the patients had received prior hormonal therapy, chemotherapy, or radiation. The prostates were fixed in 10% neutral-buffered formalin and sliced serially at approximately 3 to 4-mm intervals. Slices were further sectioned to fit into standard embedding cassettes and labeled to allow full specimen reconstruction. Lesions of high-grade PIN and carcinoma were demarcated with ink on the coverslips.

### PIA DEFINITION

The morphologic definition of PIA<sup>10</sup> encompasses both simple atrophy<sup>7</sup> and postatrophic hyperplasia,<sup>7–9</sup> in association with variable amounts of inflammatory cells and stromal fibrosis.

### PIN DEFINITION

PIN was classified according to the consensus obtained at an International Workshop.<sup>21</sup> High-grade PIN is composed of cells with histologic features of prostate adenocarcinoma occurring within pre-existing prostatic acini/ducts. Cell and nuclear crowding is present. Nuclei are enlarged and hyperchromatic and often have prominent nucleoli. Lesions with similar morphology, but in which most of the cells lacked prominent nucleoli, were classified as low-grade PIN.

### DEFINING AND CATALOGUING INDIVIDUAL LESIONS

Any high-grade PIN-containing acinus/duct within 1 mm of any other similar acinus/duct was considered part of the same lesion. A similar approach was used with the carcinoma lesions. The 1-mm boundary of uninvolved tissue was used to separate individual high-grade PIN and/or carcinoma lesions and was estimated by using the diameter of a 20× field from an Olympus BX40 fitted with a 10× ocular. Although any cutoff using two-dimensional analysis to examine three-dimensional structures is somewhat arbitrary, we used 1 mm instead of the traditional 2 mm for lesion mapping in the prostate, as attempts to use a 2-mm boundary often left no way to separate the individual lesions. We recorded the location of each lesion and its phenotype in accordance with the following scheme: (a) lesion type (ie, high-grade PIN or carcinoma); (b) prostate zone (ie, peripheral zone/transition zone/central zone/uninterpretable); (c) Gleason score (if applicable); (d) lesion size (greatest diameter); (e) topographic relationships between the lesion and PIA. Carcinoma volumes were measured by computerized analysis.<sup>22</sup>

### TOPOGRAPHIC RELATIONS

The topographic relation was described as merging when the neoplastic-appearing epithelium of the high-grade PIN or carcinoma merged directly with PIA within a given acinus or duct. Lesions were described as adjacent when the neoplastic-appearing epithelium abutted, but did not merge with, PIA. In this case, the two lesions were in very close proximity (less than ~100 μm) with only a small amount of intervening stroma, but did not merge directly within a given acinus/duct. Lesions were described as near when the individual duct/acinus of high-grade PIN or carcinoma was separated from a distinct acinus/duct containing PIA by less than 1 mm. Lesions were described as distant when the high-grade PIN or carcinoma lesion was more than 1 mm from any PIA focus.

## RESULTS

The patients' ages ranged from 36 to 66 years (mean 53). Thirteen patients were white and one was African American. The mean preoperative serum prostate-specific antigen level was 6.1 ng/mL (range 0.7 to 19.9). All prostatectomy specimens were Stage pT2N0Mx. The mean prostate weight was 61.9 g (range 35.1 to 92.5). The total number of carcinoma lesions in the 14 specimens was 79 (mean 5.4, range 1 to 13). The mean total volume of carcinoma for each prostatectomy specimen was 0.12 cc (range 0.02 to 0.48). Seventy-two (91.1%) of the carcinoma lesions were found in the peripheral zone, 6 (7.6%) were in the transition zone, and 1 (1.3%) was in an indeterminate location.

The total number of high-grade PIN lesions was 629 (mean 43, range 21 to 71). Of the 629, 585 (93.0%) were found in the peripheral zone, 8 (1.3%) were in the transition zone, and 19 (3.0%) were in the central zone; 17 (2.7%) were in an indeterminate location. The mean greatest dimension for the high-grade PIN lesions was 2.16 mm (range 0.05 to 28).

High-grade PIN merged with PIA in 267 (42.5%) of the 629 lesions (Fig. 1). High-grade PIN was adjacent to PIA in 57 lesions (9%), near to PIA in

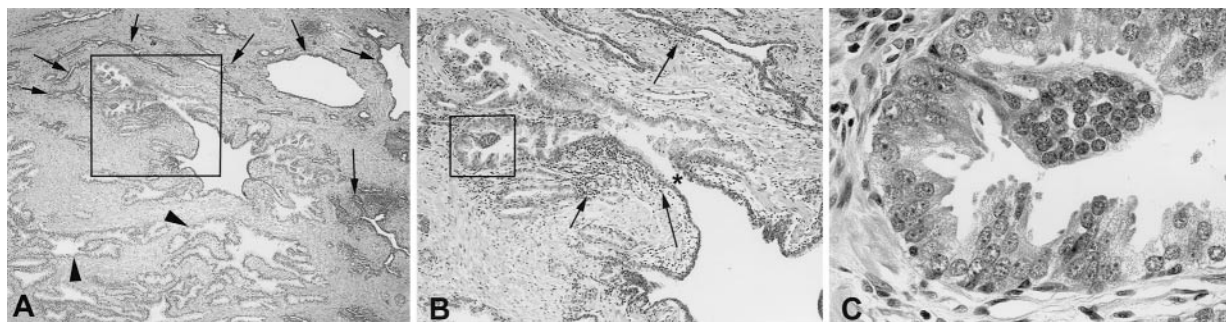


FIGURE 1. High-grade PIN merging with PIA. (A) Low power view of a focus of PIA showing a single prostatic acinus (center) illustrating merging of atrophic epithelium with epithelium containing high-grade PIN. Arrows indicate atrophic acini; arrowhead indicates normal-appearing acini. Hematoxylin-eosin stain, original magnification  $\times 40$ . (B) Medium power view of area outlined in part A. The asterisk denotes area of transition between atrophic epithelium and PIN. Arrows indicate chronic inflammatory infiltrate composed predominantly of lymphocytes (also visible in part A). Hematoxylin-eosin stain, original magnification  $\times 100$ . (C) High power view of area outlined in part B showing focus of high-grade PIN involving the periphery of the otherwise atrophic acinus. Note enlarged nuclei and numerous prominent nucleoli. Hematoxylin-eosin stain, original magnification  $\times 600$ .

233 lesions (37%), and distant from PIA in 72 lesions (11.5%).

Some PIN lesions contained clusters of cells with nuclear atypia, including nuclear enlargement, nuclear hyperchromasia, and variability in size and shape. However, they did not meet strict criteria for high-grade PIN, since most of the cells lacked prominent nucleoli. Although interobserver reproducibility among pathologists is not high when it comes to low-grade PIN,<sup>23</sup> these atypical cells were considered low-grade PIN for the purposes of this study. Since previous data are lacking concerning this, we examined a subset of the high-grade PIN lesions ( $n = 70$ , encompassing five lesions chosen at random from each prostatectomy specimen) to determine the frequency at which both high and low-grade PIN were found in proximity. Of the 70 high-grade PIN lesions, 40 (57%) contained low-grade PIN, either within the same acini/duct as the high-grade PIN or within a 1-mm boundary of the lesion.

In some lesions containing high-grade PIN, an apparent progression in the atrophic-appearing cells was evident, from cells containing no nuclear atypia to those with mild nuclear atypia to those containing severe nuclear atypia with frequent prominent nucleoli; the latter is diagnostic of high-grade PIN. Several investigators have previously noted that cells in focal atrophy can have some mild nuclear atypia,<sup>9,24</sup> which has generally been considered "reactive" atypia. Thus, in the subset of 70 high-grade PIN lesions, we documented how often associated atrophy containing nuclear atypia was present and how often an apparent morphologic progression or transition within the same gland/acinus between atrophy and PIN had occurred. Of the 70 lesions, 55 (79%) showed areas of

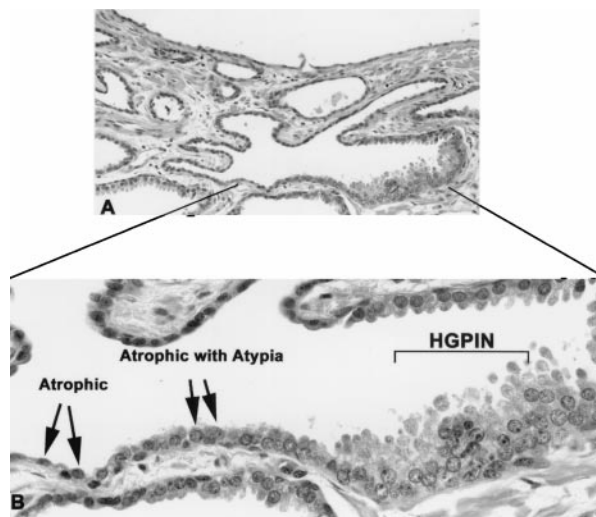


FIGURE 2. Morphologic transitions between atrophy and PIN. (A) Medium power view of a focus containing atrophy merging with high-grade PIN. Hematoxylin-eosin stain, original magnification  $\times 100$ . (B) High power view of area indicated in part A. Note apparent progression in atrophic cells from those containing no atypia (atrophic) to those containing mild nuclear atypia (atrophic with atypia) to those of PIN. The atypical atrophic cells are characterized by slight nuclear enlargement and occasional, somewhat prominent, nucleoli. High-grade PIN cells show marked nuclear enlargement, chromatin clumping, nuclear overlapping, and large prominent nucleoli. Hematoxylin-eosin stain, original magnification  $\times 600$ .

focal atrophy with atypia, and 33 (49%) of the 70 exhibited a morphologic transition (Fig. 2).

Carcinoma did not merge with PIA. It was adjacent to PIA in 24 (30.4%) of 79 lesions, near PIA in 46 (58.2%), and distant from PIA in 9 lesions (11.4%).

Carcinoma merged with high-grade PIN in 18 (23%) of 79 lesions, was adjacent to high-grade PIN in 11 (14%), was near high-grade PIN in 26 (33%), and was distant from high-grade PIN in 24 lesions (30%).

### COMMENT

In our previous study of focal atrophy of the prostate,<sup>10</sup> we selected radical prostatectomy specimens containing significant volumes of carcinoma. In that study, we identified morphologic merging between PIA and high-grade PIN in 34% of the PIA lesions. The present study was performed to independently validate this finding in a different set of patients, using an inverse approach. In the present study, we identified high-grade PIN and carcinoma lesions and sought to determine how often they merged with PIA. We attempted to minimize two pitfalls that can result from this type of approach. First, when specimens containing large carcinoma volumes are used, it is possible that some of the high-grade PIN lesions represent intraprostatic dissemination of carcinoma<sup>25</sup> and not de novo pre-neoplastic lesions. Second, atrophy and inflammation in specimens containing large volumes of carcinoma might be secondary to the carcinoma itself.

We have now formally verified that high-grade PIN often occurs in the setting of PIA and that morphologic transitions between high-grade PIN and PIA occur frequently within the same acinus/duct. Our finding that 42% of high-grade PIN lesions merged directly with PIA most likely was an underestimate, since it is possible that the high-grade PIN and PIA foci merge at a level outside the section plane.

Although this study does not prove that atrophic epithelium gives rise to PIN directly, the finding that the merging of these lesions is common is consistent with the hypothesis of a precursor-progeny relation. At this point, however, it cannot be ruled out that since PIA is a common lesion, spatial proximity and even merging may be chance events. More definitive proof will require additional studies, perhaps showing similar molecular-genetic alterations in PIA and PIN. The preliminary studies of this are suggestive that focal atrophy may contain changes in the copy number of chromosome 8, a common finding in high-grade PIN and prostate carcinoma.<sup>26,27</sup>

In the present study, we also found frequent spatial associations between small carcinoma lesions and PIA. Although we agree with the study of McNeal,<sup>28</sup> in that no carcinoma lesions were identified as merging with PIA, carcinoma lesions were often adjacent to (30%) or near (58%) PIA lesions. This number was higher than the percentage of carci-

noma lesions within 1 mm of high-grade PIN (70%). This finding supports the notion that some forms of prostate atrophy may directly give rise to carcinoma, as has been previously suggested.<sup>8,20</sup>

Our present findings appear at odds with a recent study by Anton *et al.*,<sup>29</sup> who concluded that at least one form of focal atrophy, postatrophic hyperplasia (PAH), was not associated spatially with carcinoma. They identified PAH lesions and found that carcinoma was present either within the PAH lesion, or within 2 mm, in 33% of the PAH lesions using radical prostatectomy specimens. When they examined the mirror image of the prostate that did not contain PAH, they found that carcinoma was present within 2 mm of that area 40% of the time. However, Anton *et al.*<sup>29</sup> only examined PAH, which is a subset of what we defined as PIA. Although PIA is quite prevalent, occurring in approximately 85% of all prostates at autopsy,<sup>30</sup> and a significant percentage of PIA lesions contain some PAH, pure PAH lesions as examined by Anton *et al.*<sup>29</sup> are less common, occurring in approximately 18% to 32% of prostatectomy specimens or cystoprostatectomy specimens.<sup>9</sup> Although it did not reach statistical significance, Anton *et al.* did find more PAH (9 of 28 [32%]) in patients with carcinoma than in patients without carcinoma (3 of 16 [19%]). In the study by Anton *et al.*,<sup>29</sup> they did not determine whether atrophy was topographically related to high-grade PIN, but focused solely on carcinoma.

In another recent study, no significant difference was found between the presence of atrophy in patients containing carcinoma or high-grade PIN compared with controls without carcinoma or high-grade PIN.<sup>30</sup> However, it is possible that what is important is not the mere presence of any focal atrophy, but the overall extent of PIA in cases versus controls and the topographic relation of atrophy to high-grade PIN and carcinoma.

In Bostwick's progression model of PIN to carcinoma, the transition between normal, low-grade PIN, high-grade PIN, and then carcinoma is continuous.<sup>6</sup> Few epidemiologic, morphologic, or molecular genetic studies have examined the relation between low and high-grade PIN development. In part, this relates to the difficulty in distinguishing low-grade PIN from normal tissue on the one hand and high-grade PIN on the other.<sup>23</sup> Nevertheless, we found that lesions that could be considered low-grade PIN often coexisted with high-grade PIN, suggesting either that high-grade PIN is derived from low-grade PIN or that high and low-grade PIN arise concomitantly. In either case, in our current working model we would interpose atrophic epithelium, at least at times, between normal epithelium and high-grade PIN.

## CONCLUSIONS

We have documented frequent morphologic transitions between high-grade PIN and focal atrophy of the prostate and frequent occurrences of small carcinoma lesions in the vicinity of focal atrophy. Although these findings are not definitive proof that PIA directly gives rise to PIN and/or carcinoma, they are consistent with such a hypothesis. Additional studies that will aid in testing this hypothesis are in progress, including autopsy studies to determine whether the extent of PIA is greater in populations with a greater prevalence of carcinoma. Also, molecular genetic studies to determine whether similar somatic DNA alterations are present in some PIA lesions and adjacent high-grade PIN and carcinoma and animal studies to determine whether manipulation of the host immune response results in altered susceptibility to prostate carcinogenesis should shed additional light on the present findings.

**ACKNOWLEDGMENT.** To Jonathan I. Epstein, M.D. and Jack Clark, M.D. for their assistance in the preparation of this manuscript.

## REFERENCES

1. McNeal JE, and Bostwick DG: Intraductal dysplasia: a premalignant lesion of the prostate. *Hum Pathol* 17: 64–71, 1986.
2. Kastendieck H: Correlations between atypical primary hyperplasia and carcinoma of the prostate: a histological study of 180 total prostatectomies. *Pathol Res Pract* 169: 366–387, 1980.
3. McNeal JE, Villers A, Redwine EA, *et al*: Microcarcinoma in the prostate: its association with duct-acinar dysplasia. *Hum Pathol* 22: 644–652, 1991.
4. Bostwick DG, Pacelli A, and Lopez-Beltran A: Molecular biology of prostatic intraepithelial neoplasia. *Prostate* 29: 117–134, 1996.
5. McNeal JE: Origin and development of carcinoma in the prostate. *Cancer* 23: 24–34, 1969.
6. Bostwick DG, and Brawer MK: Prostatic intra-epithelial neoplasia and early invasion in prostate cancer. *Cancer* 59: 788–794, 1987.
7. Ruska KM, Sauvageot J, and Epstein JI: Histology and cellular kinetics of prostatic atrophy. *Am J Surg Pathol* 22: 1073–1077, 1998.
8. Franks LM: Atrophy and hyperplasia in the prostate proper. *J Pathol Bacteriol* 68: 617–621, 1954.
9. Chevillet JC, and Bostwick DG: Postatrophic hyperplasia of the prostate: a histologic mimic of prostatic adenocarcinoma. *Am J Surg Pathol* 19: 1068–1076, 1995.
10. De Marzo AM, Marchi VL, Epstein JI, *et al*: Proliferative inflammatory atrophy of the prostate: implications for prostatic carcinogenesis. *Am J Pathol* 155: 1985–1992, 1999.
11. Liavag I: Mitotic activity of prostatic epithelium: a study by means of Colcemid. *Acta Pathol Microbiol Scand* 73: 19–28, 1968.
12. Feneley MR, Young MP, Chinyama C, *et al*: Ki-67 expression in early prostate cancer and associated pathological lesions. *J Clin Pathol* 49: 741–748, 1996.
13. Ames BN, Gold LS, and Willett WC: The causes and prevention of cancer. *Proc Natl Acad Sci USA* 92: 5258–5265, 1995.
14. McNeal JE: Prostate, in Sternberg SS (Ed): *Histology for Pathologists*. Philadelphia, Lippincott-Raven, 1997, pp 997–1017.
15. De Marzo AM, Nelson WG, Meeker AM, *et al*: Stem cell features of benign and malignant prostate epithelial cells. *J Urol* 160(6 Pt 2): 2381–2392, 1998.
16. Giannulis I, Montironi R, Galluzzi CM, *et al*: Frequency and location of mitoses in prostatic intraepithelial neoplasia (PIN). *Anticancer Res* 13: 2447–2451, 1993.
17. Montironi R, Magi Galluzzi CM, Marina S, *et al*: Quantitative characterization of the frequency and location of cell proliferation and death in prostate pathology. *J Cell Biochem Suppl* 19: 238–245, 1994.
18. Bonkhoff H, Stein U, and Remberger K: The proliferative function of basal cells in the normal and hyperplastic human prostate. *Prostate* 24: 114–118, 1994.
19. McNeal JE, Haillot O, and Yemoto C: Cell proliferation in dysplasia of the prostate: analysis by PCNA immunostaining. *Prostate* 27: 258–268, 1995.
20. Liavag I: Atrophy and regeneration in the pathogenesis of prostatic carcinoma. *Acta Pathol Microbiol Scand* 73: 338–350, 1968.
21. Drago JR, Mostofi FK, and Lee F: Introductory remarks and workshop summary. *Urology* 39: 2–3, 1992.
22. Partin AW, Epstein JI, Cho KR, *et al*: Morphometric measurement of tumor volume and percent of gland involvement as predictors of pathological stage in clinical stage B prostate cancer. *J Urol* 141: 341–345, 1989.
23. Epstein JI, Grignon DJ, Humphrey PA, *et al*: Interobserver reproducibility in the diagnosis of prostatic intraepithelial neoplasia. *Am J Surg Pathol* 19: 873–886, 1995.
24. Epstein JI: Non-neoplastic diseases of the prostate, in Bostwick DG, and Eble JN (Eds): *Urologic Surgical Pathology*. St Louis, Mosby, 1997, pp 306–340.
25. McNeal JE, and Yemoto CE: Spread of adenocarcinoma within prostatic ducts and acini: morphologic and clinical correlations. *Am J Surg Pathol* 20: 802–814, 1996.
26. Macoska JA, Trybus TM, and Wojno KJ: 8p22 loss concurrent with 8c gain is associated with poor outcome in prostate cancer. *Urology* 55: 776–782, 2000.
27. Shah R, Mucci NR, Pelok GD, *et al*: Proliferative inflammatory atrophy in prostate cancer: implications as a potential neoplastic precursor (abstract). *Mod Pathol* 13: 108A, 2000.
28. McNeal JE: Morphogenesis of prostatic carcinoma. *Cancer* 18: 1659–1666, 1965.
29. Anton RC, Kattan MW, Chakraborty S, *et al*: Postatrophic hyperplasia of the prostate: lack of association with prostate cancer. *Am J Surg Pathol* 23: 932–936, 1999.
30. Billis A: Prostatic atrophy: an autopsy study of a histologic mimic of adenocarcinoma. *Mod Pathol* 11: 47–54, 1998.